

慈濟醫院跨院區住院醫師教學PPT

Testicular Tumor

Based on Campbell-Walsh-Wein's Urology 12th ed. Chapters 76-78,
Taiwan Cancer Registry, and Our Experience

大林慈濟泌尿科
盧志明醫師

March 29, 2022

ICD10 - C62

- Testis cancer

- Germ Cell Tumor -
GCT

- Seminoma

- Nonseminoma
(NSGCT)

- Embryonal carcinoma

- Yolk sac tumor

- Choriocarcinoma

- Teratoma

- Non-GCTLeydig cell
tumor

- Leydig cell tumor

- Sertoli cell tumor

- Sex cord-stromal
tumors

- (others)

組織形態	男性			
	個案數	各形態百分比	細胞或病理證實數	細胞或病理證實百分比
精細胞瘤	145	51.24	145	100.00
卵黃囊瘤	7	2.47	7	100.00
胚胎性癌	13	4.59	13	100.00
混合性生殖細胞瘤	93	32.86	93	100.00
惡性畸胎瘤	11	3.89	11	100.00
絨毛膜癌	2	0.71	2	100.00
非特定生殖細胞瘤	4	1.41	4	100.00
性索基質腫瘤	2	0.71	2	100.00
其他惡性腫瘤	6	2.12	6	100.00
惡性淋巴瘤 ¹	18		18	100.00
總計 ²	283	100.00	283	100.00

註：1. 自96年癌症登記報告起，惡性淋巴瘤（ICD-O-3 M-CODE請見p.496附錄五）從各部位獨立出來計算發生率，並納入排名。

2. 個案數的總計不包含惡性淋巴瘤個案數。

Epidemiology

Testis cancer is the **most common cancer** among men aged **20-40 years**, and the **2nd most common cancer** among males aged **15-19 years**

Most common between the ages of **15** and **55**

Peaking ages: **25-35**

Incidence by area: Scandinavia, Western Europe, and Australia-New Zealand > US, UK > Africa, Asia

Incidence by race: non-Hispanic whites > Hispanics > blacks > Asians

民國108年，睪丸惡性腫瘤發生個案數占全部惡性腫瘤發生個案數的0.23%，當年因此惡性腫瘤死亡人數占全部惡性腫瘤死亡人數的0.03%。發生率的排名於男性為第20位；死亡率的排名於男性為第33位。民國108年初次診斷為睪丸惡性腫瘤者共計283人，占男性生殖器官(ICD-O-3 C60 – C63)個案數的3.77%；當年死因為睪丸惡性腫瘤者共計16人。

項 目	發生個案		項 目	死亡個案	
	男性			男性	
個案數(人)	283		個案數(人)	16	
年齡中位數	31		年齡中位數	33	
粗率(每10萬人口)	2.42		粗率(每10萬人口)	0.14	
年齡標準化率 ² (每10萬人口)	2.37		年齡標準化率 ² (每10萬人口)	0.12	
年齡標準化率 ³ (每10萬人口)	2.54		年齡標準化率 ³ (每10萬人口)	0.12	

註：1. 自 96 年癌症登記報告起，惡性淋巴瘤從各部位獨立出來計算發生率，並納入排名。

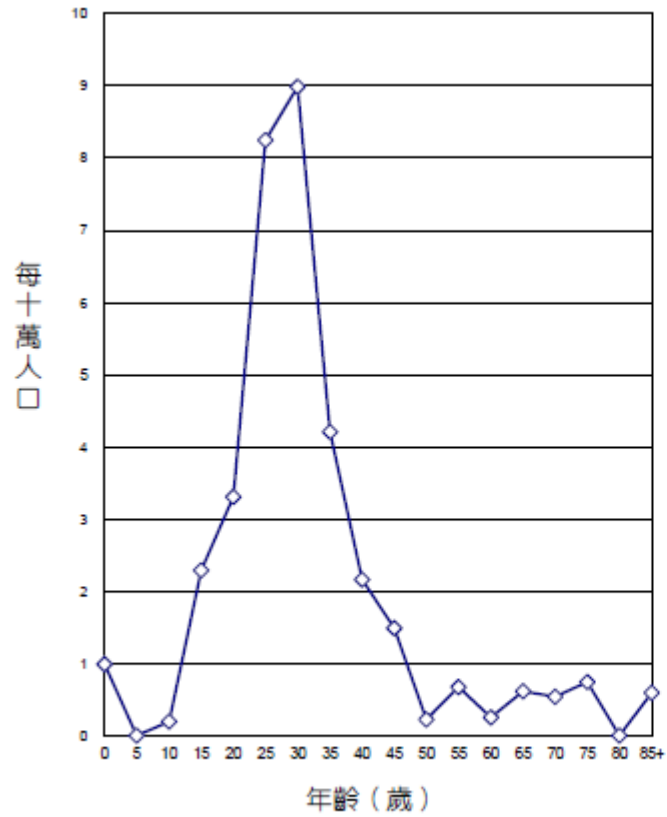
2. 3. 年齡標準化率²係使用 1976 年世界標準人口為標準人口，年齡標準化率³係使用 2000 年世界標準人口為標準人口。

民國108年，睪丸惡性腫瘤發生個案數占全部惡性腫瘤發生個案數的0.23%，當年因此惡性腫瘤死亡人數占全部惡性腫瘤死亡人數的0.03%。發生率的排名於男性為第20位；死亡率的排名於男性為第33位。民國108年初次診斷為睪丸惡性腫瘤者共計283人，占男性生殖器官(ICD-O-3 C60 – C63)個案數的3.77%；當年死因為睪丸惡性腫瘤者共計16人。

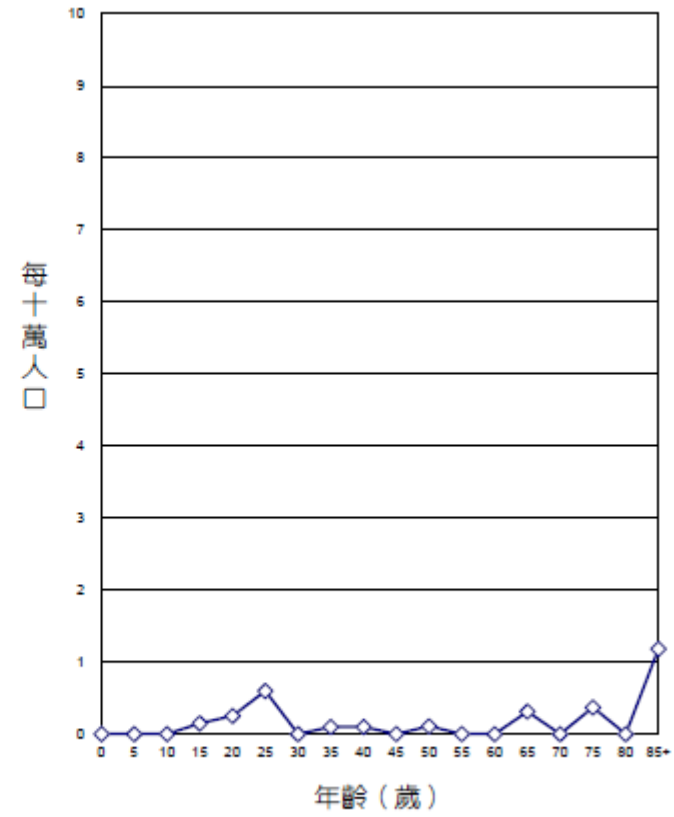
項 目	發生個案		項 目	死亡個案	
	男性			男性	
個案數(人)	283		個案數(人)	16	
年齡中位數	31		年齡中位數	33	
粗率(每10萬人口)	2.42		粗率(每10萬人口)	0.14	
年齡標準化率 ² (每10萬人口)	2.37		年齡標準化率 ² (每10萬人口)	0.12	
年齡標準化率 ³ (每10萬人口)	2.54		年齡標準化率 ³ (每10萬人口)	0.12	

註：1. 自 96 年癌症登記報告起，惡性淋巴瘤從各部位獨立出來計算發生率，並納入排名。

2. 3. 年齡標準化率²係使用 1976 年世界標準人口為標準人口，年齡標準化率³係使用 2000 年世界標準人口為標準人口。



年齡別發生率，民國108年



年齡別死亡率，民國108年

Risk Factors

5 Well-established factors

White race

Cryptorchidism (4-6 folds)

FH of testis cancer

PH of testis cancer

Germ cell neoplasia in situ (GCNIS)

Other factors

Infertile and subfertile men

Birth-cohort effects

Early exposure to endocrine-disrupting chemicals

GCT

Germ cell tumor

GCT

Pathogenesis (1/3)

70%-80% of postpubertal GCTs contain extra copies of genetic material from the short arm of 12 appearing as an isochromosome ($i[12p]$)

Genetic material can be demonstrated with **fluorescent in situ hybridization**

Used in the diagnosis of **GCT** (e.g., for carcinomas of unknown primary) and non-GCT somatic malignancy arising from malignant transformation of **teratoma**

GCT

Pathogenesis (2/3)

- 5% of GCT originate at **extragonadal** sites
- Most commonly **mediastinum and retroperitoneum.**
- Primary **mediastinal** NSGCTs **poor** prognosis.
- Teratoma is histologically benign.
- **Teratoma is resistant to chemotherapy.**

GCT

Pathogenesis (3/3)

Teratoma is **histologically benign** but genetically unstable.

Thus it has **unpredictable** biology.

Rare teratoma has the capacity to **grow rapidly** or undergo **malignant transformation** of its ectodermal, mesodermal, and/or endodermal elements to form a non-GCT somatic malignancy.

GCT

Symptoms & Signs

Painless testis mass (common)

Acute testicular pain (rare, more common with NSGCT)

Vague scrotal discomfort or heaviness

Gynecomastia (2%, most common with Leydig cell tumors)

Back pain

Neck mass

GCT

Physical Examination

Differential Diagnosis

Epididymo-orchitis

Torsion

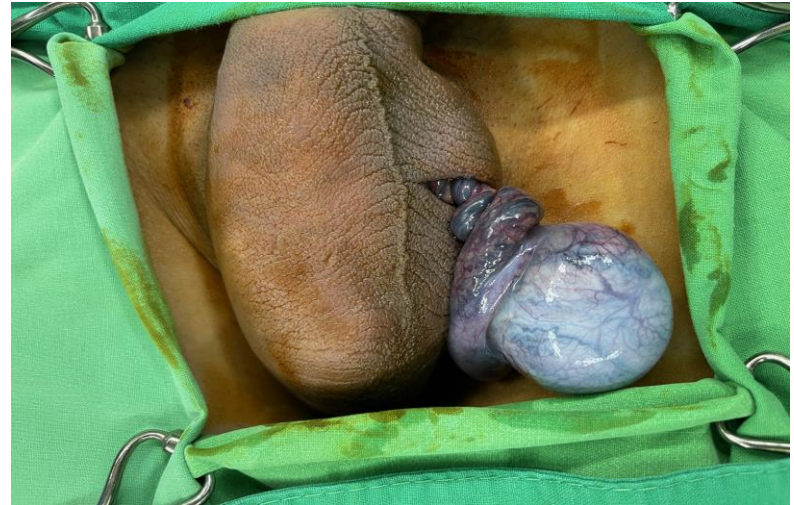Hematoma

Para-testicular neoplasm (benign or malignant)

Hernia

Varicocele

Spermatocele



Ultrasound

Ultrasound:

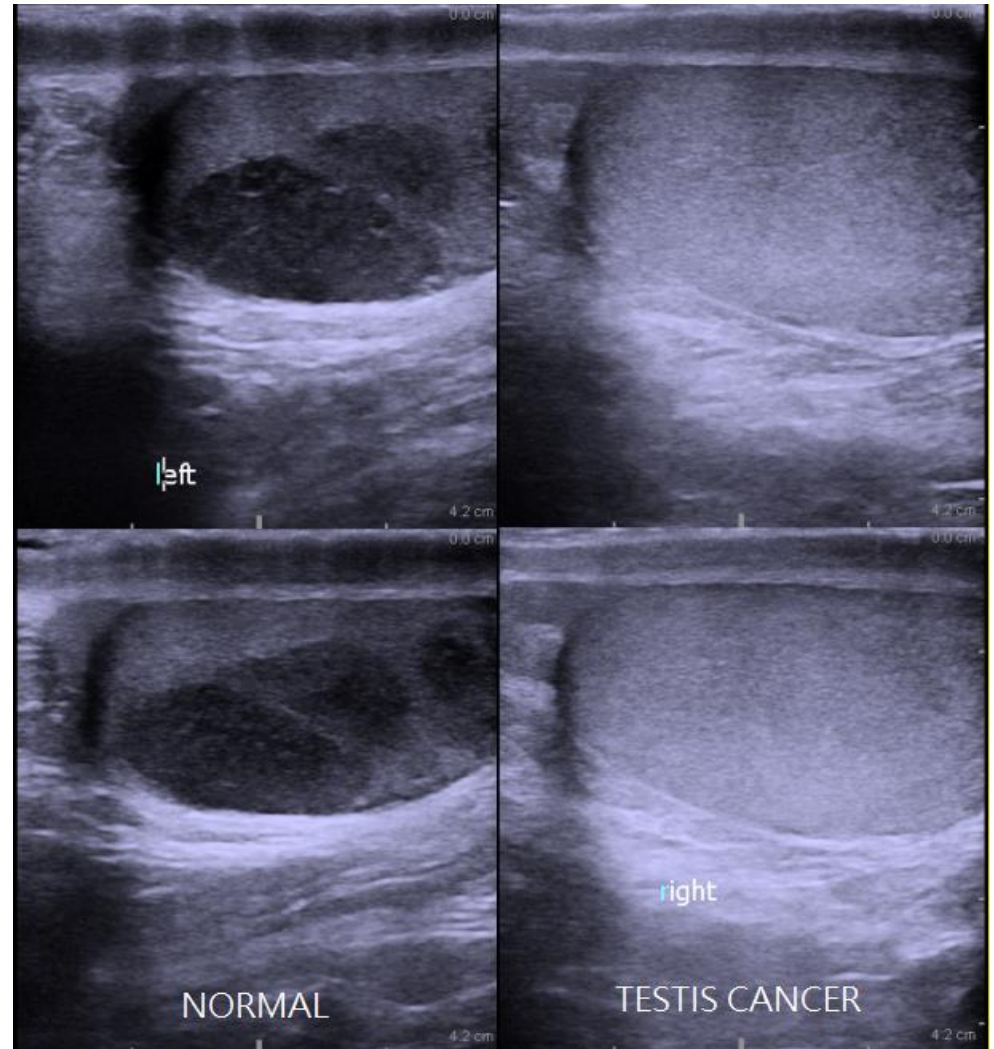
Typical GCT:

Hypoechoic and **homogeneous**,
two or more discrete lesions
may be identified.

NSGCT:

Heterogeneous echotexture
within a lesion.

Both testes should be evaluated
sonographically



GCT - Diagnostic Testing - GCT

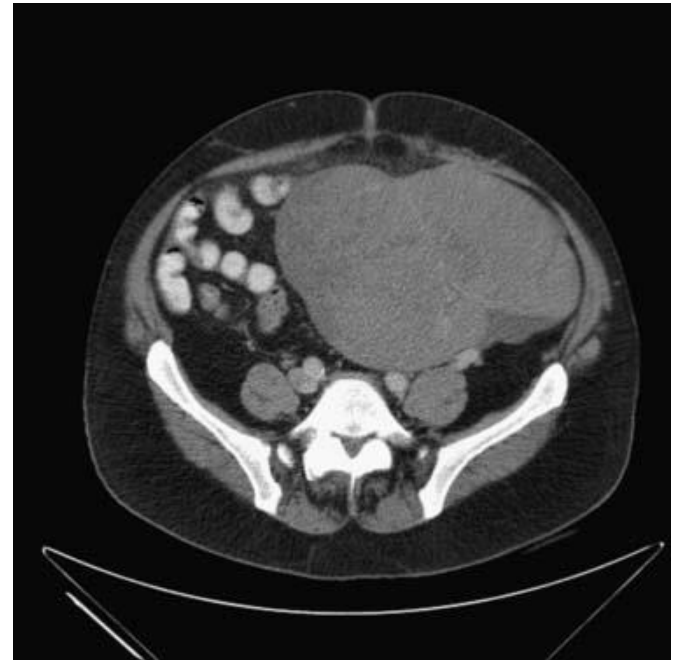
CT

The retroperitoneum is the initial site of metastatic spread in **70% to 80%** of patients with GCT.

Enlarged retroperitoneal lymph nodes are found on CT in approximately **10% to 20% of seminomas** and **60% to 70% of NSGCT**

false-negative **25% to 35%** of pathologically involved retroperitoneal lymph nodes has been a **“normal” CT scan. (CS I NSGCT)**

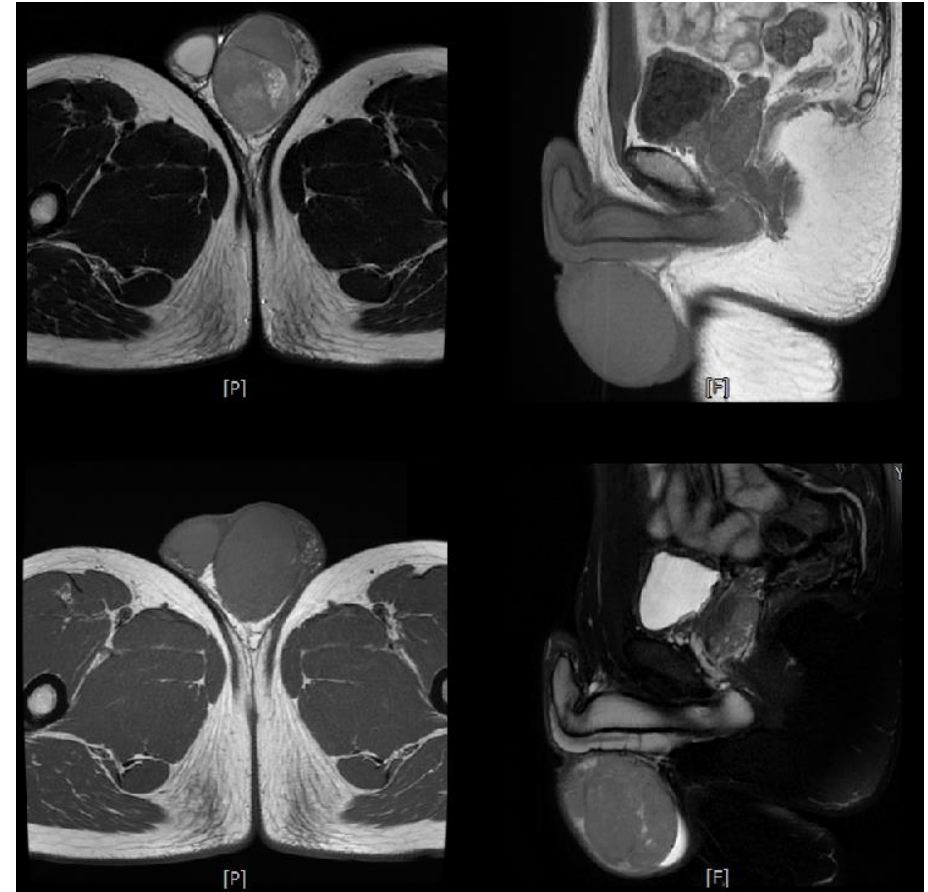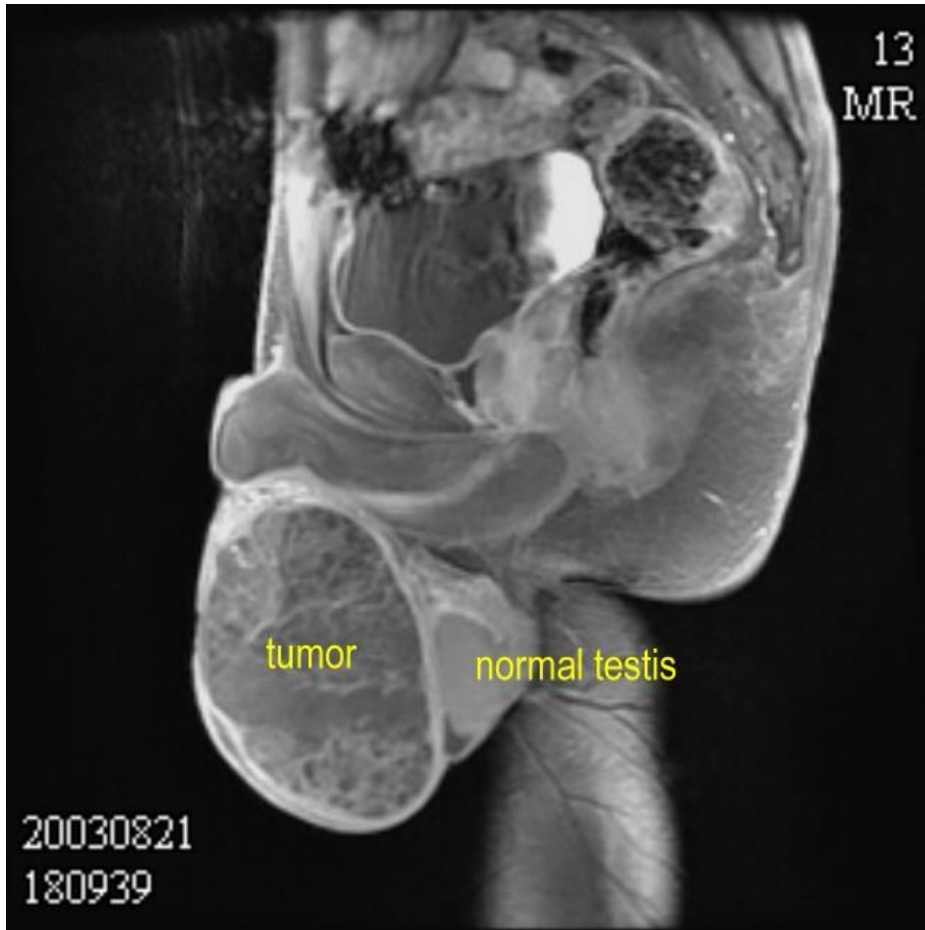
False-negative **14-20%** for seminoma



<https://radiologykey.com/testicular-germ-cell-tumors/>

GCT - Diagnostic Testing - GCT

Magnetic Resonance Imaging



GCT - Diagnostic Testing - GCT

FDG-PET

No role for FDG-PET in the routine evaluation of NSGCT and seminoma at the time of diagnosis.

GCT

STAGING

Initial Management

Radical orchiectomy should be performed with the sonographic evidence (discrete nodule, stellate scar, coarse calcification) of germ cell neoplasia in situ (GCNIS)

Risk of malignancy increases with the size of intratesticular lesions

- < 10 mm, 20-50% GCT, but majority are benign (ex. testicular cysts)
- 1-2 cm, >80%

GCT

	AFP	β-hCG	LDH
Seminoma	0	+	++
Yolk sac tumor	+++	+	+
Choriocarcinoma	0	+++	+
Embryonal carcinoma	+	+	++
Teratoma	0	0	0

+++ , Marker virtually always present in high amount and proportional to volume; ++, marker often seen in variable amount that is proportional to volume of disease; +, marker may be seen in variable amount, but not always; 0, never or seldom associated; AFP, alpha-fetoprotein; β -hCG, beta-human chorionic gonadotropin; LDH, lactate dehydrogenase.

GCT

Serum Tumor Markers

AFP

- 50% - 70% of low-stage (CS I, IIA, IIB) NSGCTs
- 60% - 80% of advanced (CS IIC, III) NSGCTs

HCG

- 20% - 40% of low-stage NSGCTs
- 40% - 60% of advanced NSGCTs

LDH

- 20% of low-stage GCT
- 20% - 60% of advanced GCT

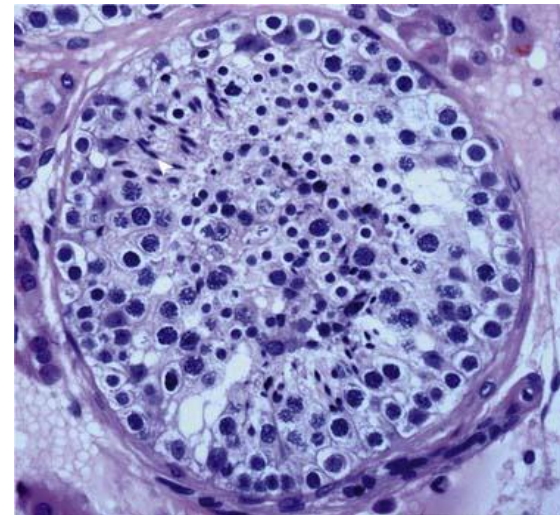
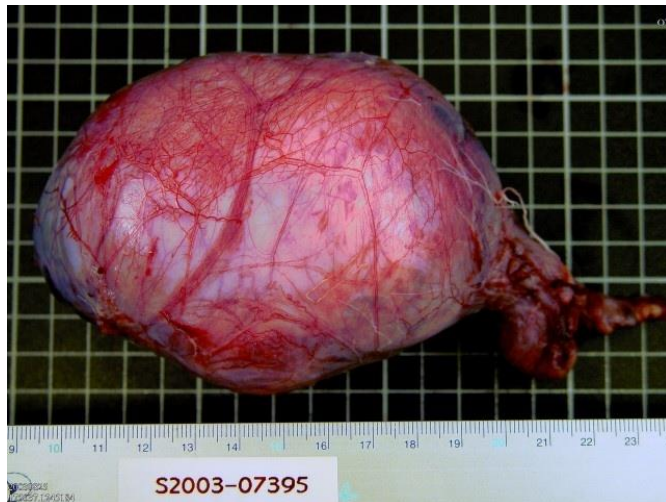
GCT

Radical Inguinal Orchiectomy

a **diagnostic tool, should be performed** among patients **suspected** of having a testicular neoplasm

Transscrotal orchiectomy or biopsy is **contraindicated**.

Radical orchiectomy establishes the **histologic diagnosis** and **primary T stage**.



GCT

Testis-Sparing Surgery

Highly controversial and has **no role** in the patient suspected of having a testicular neoplasm **with a normal contralateral testis**

May be considered for organ-confined tumors smaller than **2 to 3 cm** (< 30%)

GCT

Contralateral Testis Biopsy

5% and 9% of patients with GCT have GCNIS in the normal contralateral testis

Dieckmann KP, Skakkebaek NE: Carcinoma in situ of the testis: review of biological and clinical features. Int J Cancer 1999; 83: pp. 815-822.

Atrophic testis, cryptorchidism hx, age < 40, the risk of GCNIS in the contralateral testis has been reported in up to 36%

Dieckmann KP, Loy V: Prevalence of contralateral testicular intraepithelial neoplasia in patients with testicular germ cell neoplasms. J Clin Oncol 1996; 14: pp. 3126-3132.

Diagnosis and work-up (1/2)

- **solid intratesticular mass** should be considered a GCT
- **inguinal orchiectomy with high ligation of the spermatic cord** should be performed in men suspected of having GCT
- **Trans-scrotal orchiectomy or biopsy are to be condemned**
- **Testis-sparing surgery** for GCT is a consideration
 - **small tumor**
 - **synchronous bilateral testis masses**
 - preservation of sufficient testicular androgen production

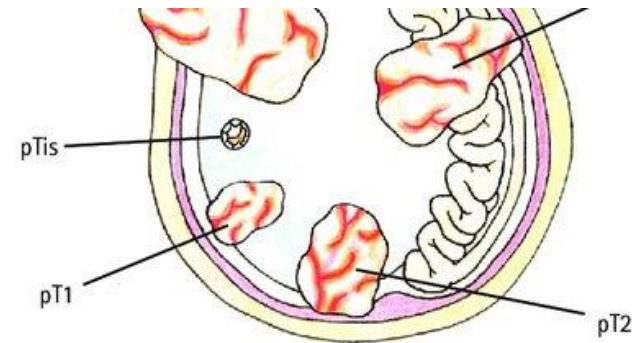
Diagnosis and work-up (2/2)

- Diagnostic **delay is common** in GCT
- **1/3** of cases are initially **misdiagnosed**
- If serum tumor marker levels elevated orchiectomy, should be measured after orchiectomy to determine if levels are declining, stable, or rising
- **Preorchiectomy** serum tumor marker levels **should not** be used in management decisions.

TNM

AJCC and UICC staging systems 2002

pTx	Primary tumor cannot be assessed
pT0	No evidence of primary tumor (e.g., histologic scar in testis)
pTis	Intratubular germ cell neoplasia (carcinoma in situ)
pT1	Tumor limited to testis and epididymis without vascular/lymphatic invasion (no LVI); tumor may invade into tunica albuginea but not tunica vaginalis
pT2	Tumor limited to testis and epididymis with vascular/lymphatic invasion (LVI) or tumor extending through tunica albuginea with involvement of tunica vaginalis
pT3	Tumor invades spermatic cord with or without vascular/lymphatic invasion
pT4	Tumor invades scrotum with or without vascular/lymphatic invasion



pTis	Germ cell neoplasia <i>in situ</i> (GCNIS)
pT1	Testis and epididymis without lympho-vascular invasion
pT2	Testis and epididymis with lympho-vascular invasion, OR involvement of tunica vaginalis
pT3	Invades spermatic cord
pT4	Invades scrotum
pN1	Lymph node mass <2cm and <5 positive nodes
pN2	Lymph node mass 2–5cm and >5 positive nodes
pN3	Lymph node mass >5cm
M1a	Distant metastases – non-regional lymph node or lung
M1b	Distant metastases – other site
LDH (U/L) hCG (mIU/ml) AFP (ng/ml)	

Serum Tumor Marker

SX	unavailable	unavailable	unavailable
S0	Within normal limits	Within normal limits	Within normal limits
S1	<1.5 x N and	<5000 and	<1000
S2	1.5-10 x N or	5000-50,000 or	1000-10,000
S3	>10 x N or	>50,000 or	>10,000

Stage

Stage 0	pTis	N0	M0	S0, SX
Stage I ^a	pT1–T4	N0	M0	SX
Stage IA	pT1	N0	M0	S0
Stage IB	pT2–T4	N0	M0	S0
Stage IS	Any patient/TX	N0	M0	S1–3
Stage II	Any patient/TX	N1–N3	M0	SX
Stage IIA	Any patient/TX	N1	M0	S0, S1
Stage IIB	Any patient/TX	N2	M0	S0, S1
Stage IIC	Any patient/TX	N3	M0	S0, S1
Stage III	Any patient/TX	Any N	M1a	SX
Stage IIIA	Any patient/TX	Any N	M1a	S0, S1
Stage IIIB	Any patient/TX	N1–N3	M0	S2
	Any patient/TX	Any N	M1a	S2
Stage IIIC	Any patient/TX	N1–N3	M0	S3
	Any patient/TX	Any N	M1a	S3
	Any patient/TX	Any N	M1b	Any S

^a Stage I testicular cancer includes the following substages:

GCT

Clinical Staging (1/3)

- GCT spread

primary tumor --> retroperitoneal LNs
→ distant metastatic sites

- The primary landing zone

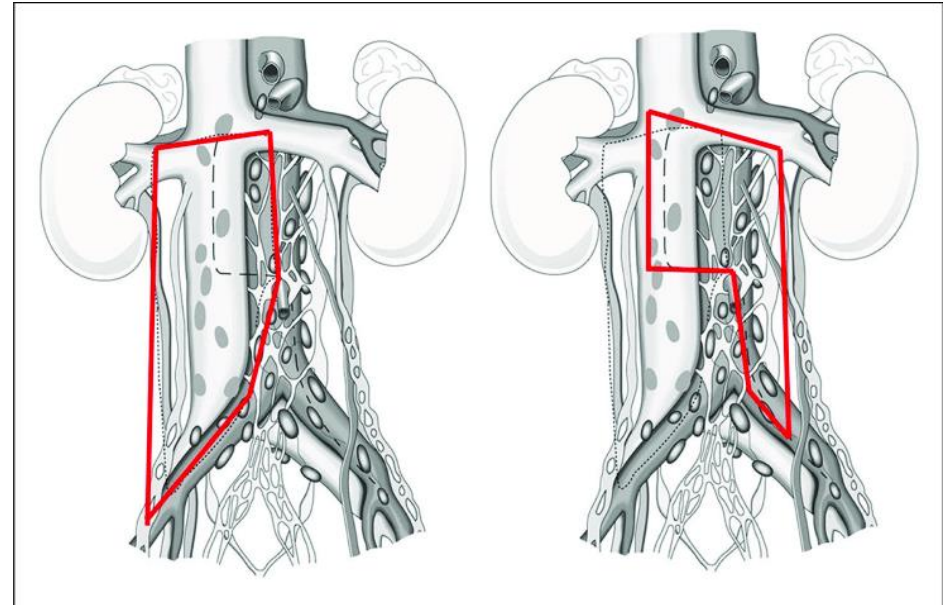
Left: para-aortic, left renal hilar LNs

Right: inter-aortocaval, paracaval LNs

- CT imaging is the optimal modality for staging the retroperitoneum
- false-negatives occur when a 1-cm cutoff is used

CS I NSGCT: 25% to 35%

Seminoma: 14% to 20%



GCT

Clinical Staging (2/3)

- Chest x-ray and CT chest
 - absence of retroperitoneal lymphadenopathy or
 - absence of elevated serum tumor marker levels.
- Chest CT
- serum tumor marker elevated or
- CT abdomen and pelvis shows metastatic disease
- Rising post-orchietomy serum tumor marker levels
 - indicate the presence of metastatic GCT and
 - should chemotherapy

GCT

Clinical Staging (3/3)

- Predict prognosis by IGCCCG risk classification
 - NSGCT: **post-orchietomy serum tumor marker levels, mediastinal primary tumor, presence of nonpulmonary visceral** metastases
 - Seminoma: **nonpulmonary visceral** metastases only
- **Sperm cryopreservation** should be offered to all patients before RPLND, C/T, or R/T

GCT

IGCCCG risk classification (1/3)

NONSEMINOMA	SEMINOMA
GOOD PROGNOSIS	
Testicular/retroperitoneal primary	Any primary site
<i>and</i>	<i>and</i>
No nonpulmonary visceral metastases	No nonpulmonary visceral metastases
<i>and</i>	<i>and</i>
Good markers—all of:	Normal AFP, any HCG, any LDH
AFP <1000 ng/mL <i>and</i>	
HCG <5000 IU/L (1000 ng/mL) <i>and</i>	
LDH <1.5 × upper limit of normal (N)	
56% of nonseminomas	90% of seminomas
5-year PFS 89%	5-year PFS 82%
5-year survival 92%	5-year survival 86%

* IGCCCG: International Germ Cell Cancer Collaborative Group risk classification for advanced GCT

GCT

IGCCCG risk classification (2/3)

NONSEMINOMA	SEMINOMA
INTERMEDIATE PROGNOSIS	
Testicular/retroperitoneal primary	Any primary site
<i>and</i>	<i>and</i>
No nonpulmonary visceral metastases	Nonpulmonary visceral metastases
<i>and</i>	<i>and</i>
Intermediate markers—any of:	Normal AFP, any HCG, any LDH
AFP ≥ 1000 –10,000 ng/mL and $\leq 10,000$ ng/mL <i>or</i>	
HCG ≥ 5000 –50,000 IU/L and $\leq 50,000$ IU/L <i>or</i>	
LDH $\geq 1.5 \times N$ and $\leq 10 \times N$	
28% of nonseminomas	10% of seminomas
5-year PFS 75%	5-year PFS 67%
5-year survival 80%	5-year survival 72%

* IGCCCG: International Germ Cell Cancer Collaborative Group risk classification for advanced GCT

GCT

IGCCCG risk classification (3/3)

POOR PROGNOSIS	
Mediastinal primary	No patients classified as poor prognosis
<i>or</i>	
Nonpulmonary visceral metastases	
<i>or</i>	
Poor serum markers—any of:	
AFP >10,000 ng/mL <i>or</i>	
HCG >50,000 IU/L (10,000 ng/mL) <i>or</i>	
LDH >10 × <i>upper limit of normal</i>	
16% of nonseminomas	
5-year PFS 41%	

* IGCCCG: International Germ Cell Cancer Collaborative Group risk classification for advanced GCT

GCT

Seminoma vs. NSGCT

- Seminoma CS I/IIA/IIB compared with NSCGT
 - lower incidence of **metastatic disease**
 - lower rates of **occult retroperitoneal**
 - lower rate of **distant metastases**

- Seminoma CS I/IIA/IIB compared with NSCGT
 - sensitivity to **radiation therapy**
 - sensitivity to **platin-based chemotherapy**
 - **Only 15%** HCG elevated
 - **Less teratoma** at metastatic sites

- **No poor-risk prognostic** category in IGCCCG criteria

GCT

TREATMENT

GCT

Treatment for GCNIS

- Germ Cell Neoplasia In Situ
 - 50% risk of developing an invasive GCT
 - within 5 years
- Radical orchiectomy or low-dose (≥ 20 Gy) radiation therapy is an effective

CS I

•The optimal management of CS I NSGCT is **controversial**.

•CS I NSGCT who choose to receive chemotherapy

-BEPx1 is the standard regimen

•Accepted treatment options (long-term survival 100%)

-**Surveillance**,

-**primary RPLND**, and

-**primary chemotherapy with BEPx2**

GCT / Treatment for NSGCT (2/6)

CS I

.A risk-adapted approach based on

-the presence of **LVI** and

-embryonal carcinoma (**EC**) predominance

.Surveillance

-for **no** risk factors

-**NOT** for poorly compliant with follow-up imaging and clinical evaluation

.Active treatment (RPLND or BEPx2) for with LVI and/or EC predominance

GCT / Treatment for NSGCT (3/6)

RPLND for CS I

• Select patients for RPLND

-normal serum tumor marker levels and

-non-bulky (<3 cm) retroperitoneal adenopathy

• For RPLND, preserving ejaculatory function should not compromise oncologic efficacy

GCT / Treatment for NSGCT (4/6)

pN2-3 / CS IIA-B

• **pathological** stage II

-adjuvant chemotherapy after primary RPLND (?)

• **reduction** in the risk of **relapse**

• **no** difference in **long-term survival**

• recommended to **pN2-3** and **noncompliant**

• CS IIA-B

-Chemotherapy and primary RPLND

-long-term cure in **95%** or more

-Favored in patient with a **high risk of occult metastasis** disease on the basis of **elevated post-orchietomy serum tumor markers** and/or **bulky (>3 cm)** retroperitoneal lymphadenopathy

GCT / Treatment for NSGCT (5/6)

CS IS, IIC, III

.CS IS, IIC, and III

-cisplatin-based chemotherapy

-regimen and number of cycles is dictated by IGCCCG risk criteria

-Good-risk: BEP*x3 or EP**x4

-intermediate- and poor-risk: BEPx4

-Survival

.Good 89-94%

.Intermediate 75-83%

.Poor-risk 41%–71%

.* BEP, bleomycin-etoposide-cisplatin

.** EP, etoposide-cisplatin

GCT

Treatment for NSGCT (6/6)

- Post-chemotherapy resection of all residual masses is based on the incidence of residual cancer (either viable malignancy or teratoma) in 50% or more of patients.
- The use of **adjuvant chemotherapy is controversial** in patients with viable malignancy in residual masses after first-line chemotherapy.

GCT / Treatment for Seminoma (1/5)

CS I

- The optimal management of **CS I seminoma** is controversial
- Accepted treatment options (long-term survival 100%)
 - Surveillance**
 - primary radiotherapy** (20–30 Gy to the para-aortic region +/- ipsilateral pelvis)
 - primary chemotherapy** with carboplatin (1–2 cycles)
- Surveillance is **not** recommended to poorly compliant
- Prognostic factors for occult metastases in CS I seminoma
 - low-risk of occult metastases (15%–20%)

GCT / Treatment for Seminoma (2/5)

CS I

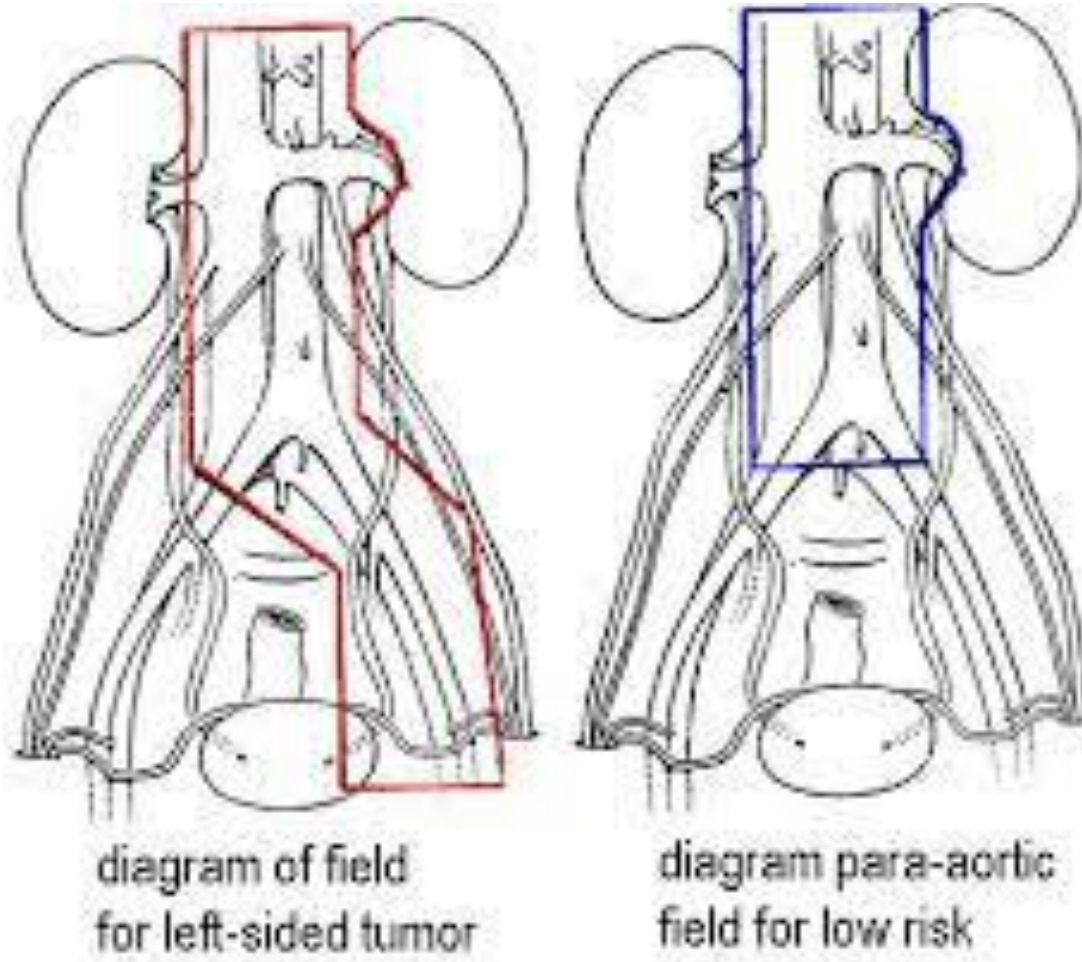
- relapse on surveillance

- Dog-leg (DL) radiotherapy (25–35 Gy)

- first-line chemotherapy for bulky retroperitoneal lymphadenopathy or distant metastases

- Primary R/T and primary C/T with single-agent carboplatin are associated with similar rates of cure and survival.

Dog-leg Radiotherapy



GCT / Treatment for Seminoma (3/5)

CS IIA-B

- non-bulky (<3 cm) retroperitoneal lymph node metastasis

- DL radiotherapy (25–35 Gy) and

- First-line chemotherapy (BEPx3 or Epx4)

- bulky (>3 cm) and/or multifocal retroperitoneal metastases

- First-line chemotherapy (BEPx3 or Epx4)

GCT / Treatment for Seminoma (4/5)

CS IIC, III

- First-line cisplatin-based chemotherapy
 - regimen and number of cycles is dictated by IGCCCG risk criteria
 - good-risk disease: BEP_{x3} or Epx₄
 - with intermediate-risk disease: BEP_{x4}

GCT

Treatment for Seminoma (5/5)

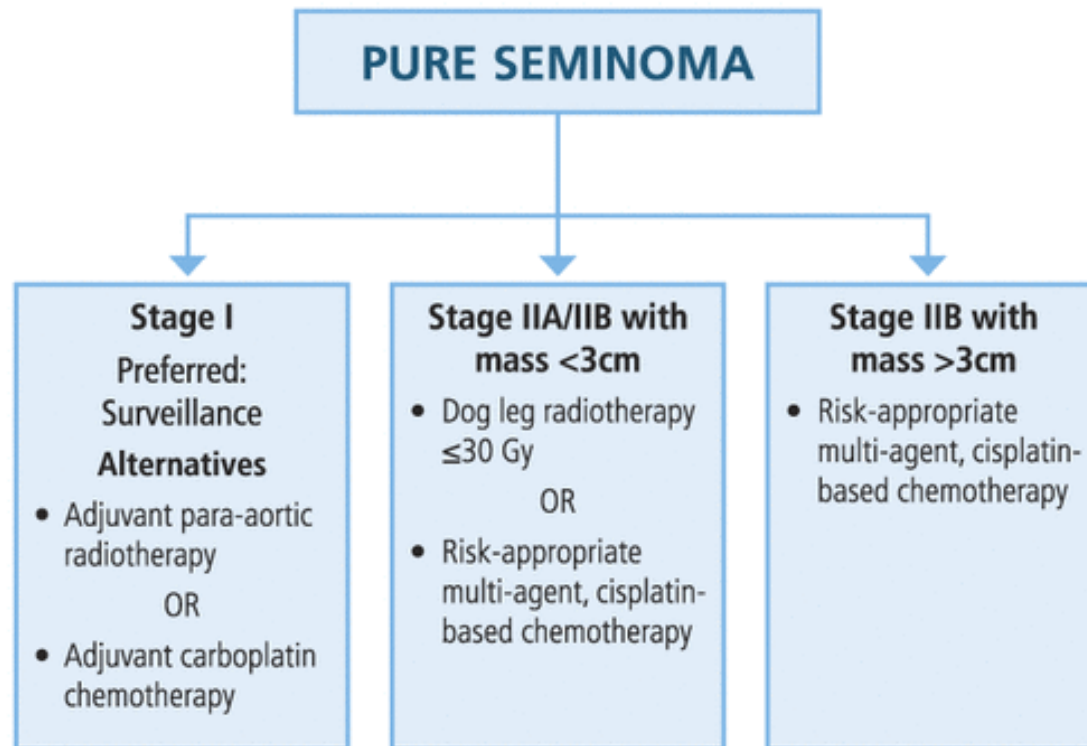
.FDG-PET imaging

- with discrete, residual masses larger than **3 cm** after first-line chemotherapy
- PET-positive then **surgical resection**
- PET-negative or less than 3 cm: observed after chemotherapy.

.Brain metastases

- associated with choriocarcinoma
- very high serum HCG level
- at risk of **intracranial hemorrhage**

DIAGNOSIS AND TREATMENT OF EARLY STAGE TESTICULAR CANCER: AUA GUIDELINE ALGORITHM



*IGCCCG good risk chemotherapy BEPx3 or EPx4.

申報治療方式*	男性	
	治療人數	百分比
手術治療	272	96.11
放射線治療	11	3.89
化學治療	95	33.57
內分泌藥物治療	1	0.35
免疫治療	1	0.35
骨髓/幹細胞移植	1	0.35
緩和照護	7	2.47
未有首次治療申報紀錄	3	1.06

申報治療方式*：每名個案所接受之治療方式均分別計數。

NGCT

Non-Germ Cell Tumor

Treatment for NGCT

- Sex Cord-Stromal Tumors: 0.4% to 4% of testis neoplasms, 90% benign and 10% malignant.
- Leydig Cell Tumors: 75% to 80% of sex cord-stromal tumors, no association with cryptorchidism, 30 to 60-year-old, CT chest-abdomen-pelvis for staging purposes. radical inguinal orchiectomy, testis-sparing surgery can be considered for tumors smaller than 3 cm, metastatic sites are the retroperitoneum and the lung,
- Sertoli Cell Tumor: <1% of testis neoplasms, testis-sparing surgery can be considered for tumors smaller than 3 cm
- Granulosa Cell Tumors
- Gonadoblastoma
- Dermoid and Epidermoid Cyst
- Adenocarcinoma of the Rete Testis

SURGERY

Radical Orchiectomy

- via an **inguinal incision**
- early **control of the spermatic cord**
- complete removal of the ipsilateral **testis, epididymis, and spermatic cord to the level of the internal inguinal ring**

Partial Orchiectomy

- NOT considered except
- tumor is polar
- measures <2 cm
- absence of contralateral testicle

Indication of RPLND

- Primary RPLND: high-risk CS 1 or low-volume CS II (N1) NSGCT with normal STMs
- PC-RPLND: after C/T, residual mass > 1 cm in the retroperitoneum with normal STMs
- Salvage PC-RPLND: after induction and salvage chemotherapy
- Desperation PC-RPLND: after C/T, elevated STMs
- Reoperative RPLND: after a prior RPLND
- Resection of late relapse: relapse of disease > 24 months after a complete response (CR) from primary chemotherapy

Auxiliary Procedures

- The most common auxiliary procedure **nephrectomy**, particularly for **left-sided or larger masses**.
- **En-bloc aortic replacement**.
- Primary **reconstruction of the IVC** when a venotomy or partial excision is required
- **Hepatic resection** should be individualized using a multidisciplinary care team.

L-RPLND & RA-RPLND

- The most common reason for conversion to an open procedure is **bleeding (<5%)**
- Effective treatment options for **low-stage NSGCTs**.
- Reports omitting chemotherapy for patients with N1 disease who underwent L-RPLND and RA-RPLND support its therapeutic efficacy.